



# Anaerobic Infections of the Lung and Improved Techniques for Recovery of Anaerobes and their Bacteriologic Identification Led to Increased Recognition of Infection

**Amir Khan<sup>1</sup>, Tristan Knight<sup>2,3</sup>, Samantha Knight<sup>1</sup> and Andrew J. Murphy<sup>4,5,\*</sup>**

Received Date:  
17/02/2022  
Revised Date:  
22/03/2022  
Accepted Date:  
10/04/2022  
Published Date  
17/04/2022

<sup>1</sup>Southern Illinois University School of Medicine, Division of Surgery, Department of General Surgery, Springfield, IL 62702, USA

<sup>2</sup>Division of Pediatric Hematology and Oncology, Department of Pediatrics, Children's Hospital of Michigan, Detroit, MI 48201, USA

<sup>3</sup>Department of Pediatrics, Wayne State University School of Medicine, Detroit, MI 48201, USA

<sup>4</sup>Department of Surgery, St. Jude Children's Research Hospital, Memphis, TN 38105, USA

<sup>5</sup>Division of Pediatric Surgery, Department of Surgery, University of Tennessee Health Science Center, Memphis, TN 38105, USA

## **Corresponding Author:**

Andrew J. Murphy\*, Division of Pediatric Surgery, Department of Surgery, University of Tennessee Health Science Center, Memphis, TN 38105, USA, Email: [andrew.murphy@stjude.org](mailto:andrew.murphy@stjude.org)

## **Citation:**

Knight S, Knight T, Khan A, Murphy AJ (2022) Anaerobic Infections of the Lung and Improved Techniques for Recovery of Anaerobes and their Bacteriologic Identification Led to Increased Recognition of Infection. *World J Case Rep Clin Img.* 2022 Feb-Apr; 1(1):1-8.

## **Copyrights**

© 2022, This article is licensed under the Creative Commons Attribution-Non-Commercial-4.0-International-License (CCBY-NC) (<https://worldjournalofcasereports.org>) Usage and distribution for commercial purposes require written permission.

## **Abstract**

Anaerobic pleuropulmonary infections usually arise from the aspiration of oral bacteria. The degree of virulence depends on host factors, especially the state of tissue oxygenation and the inoculum size. Fetid sputum, if present, frequently is diagnostic. The use of penicillin G is the preferred therapy for all forms of anaerobic pleuropulmonary infection. Anaerobic infections of the lung and pleural space are currently receiving widespread attention among practicing physicians. Improved techniques for recovery of anaerobes and their bacteriologic identification have led to increased recognition of this form of infection. Anaerobic pulmonary infections differ from aerobic bacterial pneumonia in that symptoms tend to be indolent, and response to therapy is often protracted. Obligate anaerobes are the chief constituents of normal oropharyngeal flora and produce pleuropulmonary infection in patients who are prone to aspirate.

**Keywords:** Anaerobic pleuropulmonary, Esophagus, Pneumonia, Microbiology

## Introduction

Mixed aerobic and anaerobic infection is usually a complication of macro aspiration of oropharyngeal contents. Rare causes include rupture of the esophagus and extension of intra-abdominal abscesses. Underlying pulmonary conditions such as malignancy and pulmonary infarction are present in 20% of patients with an anaerobic lung infection [1,2]. Although acute complications of macroaspiration are mainly due to a chemical injury pneumonitis (Mendelson syndrome) or infection by pathogenic aerobes in the oral flora, many of these episodes later result in mixed aerobic and anaerobic pneumonia. In-vitro cultivation of obligate anaerobes needs rigorous anaerobic methods, and susceptibility testing of obligate anaerobes is not standardized in many clinical microbiology laboratories. Various new drugs with in-vitro activity against obligate anaerobes have recently become available for empirical treatment of pneumonia [3,4].

## Routes of Infection

Bacteria can arrive in the lung in several ways:

- By aspiration of oral secretions
- By direct implantation, e.g., trauma, surgery,
- By extension from contiguous foci, e.g., subphrenic abscess,
- Through the bloodstream from distant foci

The most common factor leading to the development of anaerobic pleuropulmonary infection is an aspiration. Altered states of consciousness or dysphagia precede such infection more than 70% of the time. Of the significant causes of aspiration (see Table 1), alcoholism is the single most important. Pulmonary diseases, such as bronchogenic carcinoma and bronchiectasis, are found in 20% of cases of anaerobic pleuropulmonary infection. The remaining 10% arise from contiguous or distant abdominal foci [5-9].

**Table 1: Major Causes of Aspiration**

Alcoholism	General anesthesia
Cerebrovascular accident	Head trauma
Drug overdose or addiction	Intestinal obstruction
Esophageal disease	Seizure disorder

## Bacteriology

Until recently, the bacteriology of anaerobic pleuropulmonary infection has been poorly described. The culture of expectorated sputum does not yield accurate data since anaerobes commonly inhabit the oral cavity. Proper collection technique therefore requires:

- The bypassing of oral secretions
- Transtracheal aspiration usually yields the most valuable cultural material

Unlike aerobic pneumonia, anaerobic processes are polymicrobial, with an average of three different organisms per infection.

The organisms most frequently recovered are:

- Fusobacteria
- Pepto streptococci
- Bacteroides melaninogenicus

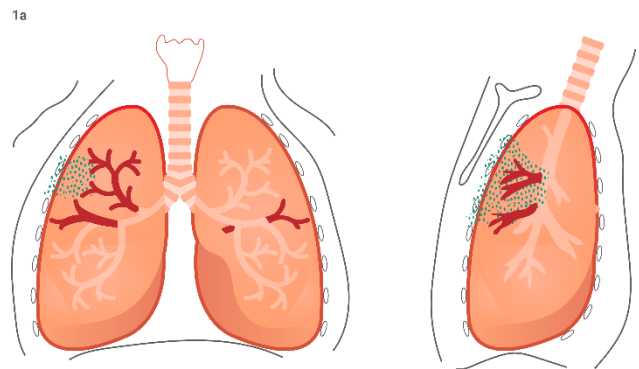
Together these represent more than 58% of isolates. *B. fragi* or *B. fragis* is recovered in less than 20% of cases. Except for *B. fragi* or *B. fragis*, the microbial flora of these infections is essentially like that in the mouth, where anaerobes outnumber aerobes by at least 10 to 1 [10]. The anaerobes originate primarily in and around gingival crevices and may achieve concentrations as high as  $10^{11}$ /ml, depending on the degree of oral hygiene. Thus, aspiration of a large inoculum by a host with impaired defenses, such as a malnourished alcoholic, can readily lead to establishing an infective process in the lung [7,11,12].

## Pathogenesis

Anaerobic growth depends primarily on a low redox potential. A lowering of this potential occurs when tissue oxygenation is impaired, either by:

- Destruction of tissue (from infection, trauma, or tumor) or
- Attenuation of the blood supply

An oxygen-poor environment allows anaerobic organisms to multiply. Moreover, polymorphonuclear leukocytes function poorly in this setting. The natural history of anaerobic pulmonary infection is illustrated in Figure 1. Aspiration of oral bacteria may result in an area of pneumonitis at the primary site of injection (see Figure 1a). If not checked by normal host defenses, this process leads to liquefactive necrosis. A lung abscess forms as the infection breaks through a bronchial wall (see Figure 1b). If infective material spills over into other pulmonary segments, more abscesses can be created. Instead, the necrotizing process extends laterally to involve the pleura, a profound inflammatory reaction ensues, and an empyema develops (see Figure 1c).



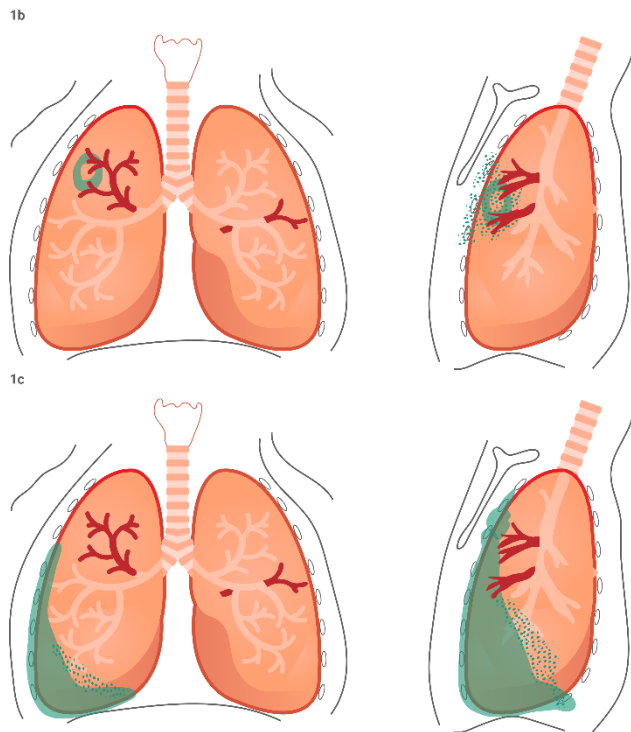


Figure 1: Types of anaerobic lung infections. a. Pneumonia. b. Lung abscess. c. Empyema

Bronchopleural fistulas occur when the necrotizing process communicates with a bronchial lumen, allowing air to enter the pleural space. All these forms of infection may, rarely, coexist. The most common sites of anaerobic pulmonary involvement are the posterior segment of the right upper lobe and the superior segment of the right and left lower lobes (see Figure 2).

The preference for infection at these three sites is related to the anatomy of the bronchial segments. Brock<sup>6</sup> demonstrated that gravity causes radiologic contrast material instilled into the trachea to flow to the most dependent pulmonary segments. When a person is recumbent (the position in which aspiration usually occurs), segmental bronchi to the posterior right upper lobe and superior right and left lower lobes point downward in the direction of the gravitational pull (see Figure 3).

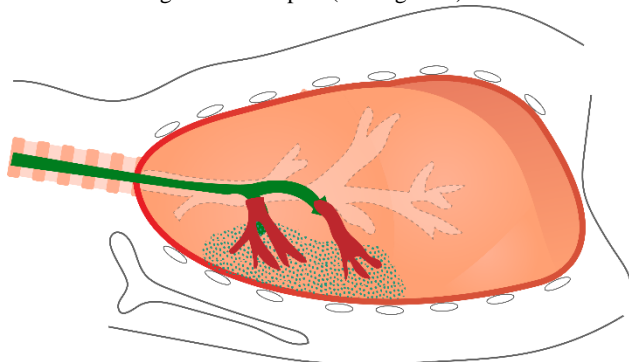


Figure 3: Recumbent position favors the gravitational flow of aspirated material to posterior segment of right upper lobe and superior segment of lower lobes

Thus, these areas receive the most significant amount of infective material. When anaerobic infections develop in other pulmonary segments, an underlying process other than an aspiration, such as bronchial occlusion from a tumor or metastatic infection, should be suspected. The primary Gram-negative species in the periodontal pocket include *Porphyromonas*, *Bacteroides*, *Prevotella*, and *Fusobacterium*. The saliva that cleans these mucosal surfaces contains these organisms. Other organisms that colonize the nasopharynx include obligate anaerobes and known aerobic pulmonary pathogens, such as *Hemophilus influenzae* and *Streptococcus pneumoniae*. Usually, anaerobic pulmonary infection is endogenously obtained by aspiration of oropharyngeal contents. Aspiration occurs among common people, especially during deep sleep, but certain patients' aspiration is thought to be of sufficient magnitude or frequency to overcome lung defenses. The aspirated material may contain adjuvants, such as necrotic tissue, food or foreign bodies, or especially virulent pathogens, or synergistic combinations of microorganisms. Individuals with an anaerobic pulmonary infection commonly have underlying conditions that predispose to aspiration, such as:

- Diabetic coma
- General anesthesia
- Loss of consciousness from a seizure
- Head trauma
- Intoxication due to alcoholism
- Other drug abuse or overdose
- Cerebrovascular accident
- Esophageal disease

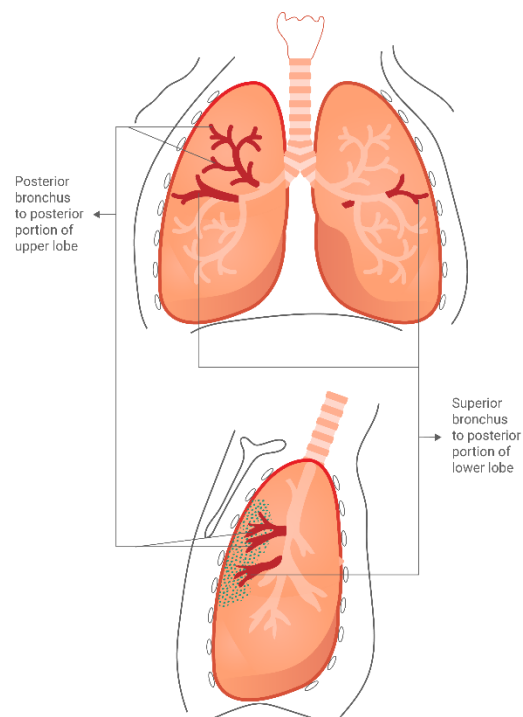


Figure 2: Bronchial pulmonary segments most frequently involved in anaerobic lung infections

Anaerobic pulmonary infection developing because of bronchogenic spread to the lung is generally referred to as primary. Hematogenous anaerobic pulmonary infection is secondary because the primary infection (endocarditis, suppurative thrombophlebitis, or bacteremia) will usually be clinically evident. Unresolved anaerobic bacterial pneumonitis will undergo necrosis in 1-2 weeks and result in one or more discrete cavities. The necrotizing infection is a lung abscess if each cavity is 2 cm or more in diameter. If there are multiple, small cavities, each less than 2 cm in diameter, the process is usually referred to as necrotizing pneumonia [13-17]. Both lung abscess and necrotizing pneumonia are thought to be different manifestations of the same pathogenetic processes. Extension of the anaerobic pulmonary infection to the pleural space may result in anaerobic empyema.

## Microbiology

When aspirated into the lower respiratory tract, there is a marked simplification of the flora to predominate only the most virulent species. Around four or five microbial species are isolated from the minimally contaminated lower respiratory secretion in these individuals. Anaerobic species, such as *Fusobacterium nucleatum*, *Prevotella melaninogenica*, and *Peptostreptococcus species* generally predominate. Also, Microaerophilic and facultative streptococci are frequently present. In few patients, the anaerobes may be mixed with facultative respiratory pathogens, such as:

- *Staphylococcus aureus*
- *H. influenzae*
- *Klebsiella pneumoniae*
- *S. pneumoniae*

The anaerobic species, different facultative microorganisms, typically produce a foul odor in clinical specimens.

## Clinical Presentations

Anaerobic infections present as four different syndromes:

- chemical pneumonitis, aspiration pneumonia, anaerobic pleuropneumonia, or primary anaerobic empyema.

Chemical pneumonitis can precede anaerobic pneumonia and is characterized by the acute onset of:

- Hypoxemia, fever, cough (often dry), dyspnea, and pleuritic pain

The foul sputum and hemoptysis characteristic of anaerobic lung abscess are absent at this stage. The risk of infection is dependent on the nature of the inoculum; many cases of aspiration pneumonitis are inflammatory alone and not infectious. Imaging may demonstrate bronchopneumonia opacities, but usually not lobar consolidation, in the aspiration-prone segments of the lung (e.g., a superior segment of the right lower lobe and a posterior segment of the right upper lobe). Acute respiratory distress syndrome is a common complication of aspiration of low pH gastric fluid. Aspiration pneumonia is identical to either CAP or HAP, except that it is seen in patients with risk factors for

macroaspiration. The rapid development of pulmonary opacities over a short period may suggest the diagnosis of aspiration pneumonia. High concentrations of pepsinogen or amylase in BAL fluid are very suggestive of this entity. Localization of opacity in a dependent lung segment has less discriminating value. Anaerobic pleuropneumonia is identified by suppuration and necrosis of lung parenchyma. Early in the course, imaging may display dense segmental opacification with multiple small lucent areas of lung necrosis (<2 cm in diameter), generally without air-fluid levels. In the absence of suitable treatment, these lesions may evolve into a primary lung abscess and empyema. Patients commonly present with fatigue, weight loss, lowgrade fever, and productive cough for some weeks after an episode of loss of consciousness. Around half describe putrid sputum, but some may have hemoptysis. Individuals appear chronically ill and toxic, with temperatures up to 39°C.

A single lung abscess >2 cm in diameter is identified in a dependent lung segment on radiography. The abscess may be multilocular. Sometimes, multiple abscesses are present in different lung segments. Primary anaerobic empyemas are generally due to *S. milleri* or *S. intermedius* rather than anaerobes. Still, anaerobes play a significant role. In these cases, the pleural presentations may dominate with less evidence of pneumonia. Also, anaerobic empyema can be seen in the absence of parenchymal lung infection when empyema develops in association with esophageal rupture or from subphrenic or other intra-abdominal abscesses.

## Microbiologic Diagnosis

Gram stain of sputum or examination of a bronchoscopically obtained specimen from a patient with anaerobic pneumonia reveals numerous polymorphonuclear leukocytes with an abundance of intracellular and extracellular bacteria. A mixture of Gram stain reactions and morphologies are typically seen, including pale-staining gram-negative rods with tapered ends (suggestive of *Fusobacterium nucleatum*), small, pale-staining gram-negative coccobacilli, and chains of tiny gram-positive cocci. As the endogenous flora of the upper respiratory tract predominantly consists of anaerobic bacteria, cultures of expectorated sputum are not appropriate for the diagnosis of anaerobic infections. With careful technique, recovery on average of 3.2 bacterial isolates, of which 80% are anaerobes, is possible in a case of mixed aerobic/anaerobic pneumonia or empyema. The most common anaerobes in pleuropulmonary infections include *F. nucleatum*, *Prevotella*, *Porphyromonas*, *Peptostreptococcus*, and *microaerophilic Streptococcus*.

The major aerobic and facultative organisms recovered in conjunction with anaerobes are *Streptococcus* species. Although *S. aureus*, various enteric gram-negative bacilli, and *Pseudomonas* may also be isolated, their significance is often questionable. Molecular techniques can often identify anaerobes in culture-negative cases.

## Diagnosis

Diagnosis of anaerobic pleuropulmonary infection depends on clinical, radiologic, and bacteriologic clues (see Table 2).

**Table 2: Clues of the Diagnosis of Anaerobic Pleuropulmonary Infection**

<b>Clinical</b>
Putrid discharge (sputum or empyema fluid)
Mild symptoms
Suspected aspiration
<b>Radiologic</b>
Lung abscess
Empyema
<b>Bacteriologic</b>
Typical appearance on Gram stain
Negative aerobic cultures

## Clinical Clues

The literature mentions putrid sputum or empyema fluid as the hallmark of this infection. Anaerobes are the only microorganisms capable of creating the fetid odor mainly due to volatile amines, short-chain fatty acids, and organic acids. However, many patients with the anaerobic pleuropulmonary infection do not have foul-smelling sputum or empyema fluid. Therefore, the absence of this sign does not rule out the presence of an anaerobic infection. Other agents such as *Mycobacterium tuberculosis*, *K. pneumoniae*, and *S. aureus* can cause similar clinical situations. A second crucial clinical clue is the subacute nature of the infection. Most patients report having symptoms for more than a week before seeking medical attention. A final clinical clue is an aspiration, which may be suspected from the history in three-fourths of patients. An old clinical axiom stated that anaerobic lung abscesses never developed in edentulous persons since poor oral hygiene provided the source of this type of infection. Subsequent studies, particularly those by Bartlett and Finegold, have disproved this. Nonetheless, the presence of periodontal or gingival disease should increase suspicion that pleuropulmonary infection may be due to anaerobes. In edentulous persons with confirmed anaerobic lung disease, a vigilant search should be done for evidence of bronchial obstruction or subdiaphragmatic foci of infection.

## Radiologic Clues

Cavity formation and pleural effusion are immediate tip-offs to the possible presence of an anaerobic process. Again, radiologic findings are not pathognomonic for any form of such infection.

## Bacteriologic Clues

The Gram stain is an essential tool for rapid assessment of the presence of anaerobes. Sputum and bronchoscopy specimens should not be used for Gram staining or anaerobic culture since such material is contaminated by oral microbial flora. Appropriate material for Gram staining can be obtained from transtracheal aspiration or thoracentesis if empyema is present.

Transtracheal aspiration should be performed only by physicians well trained in the procedure and should be avoided in patients who are uncooperative or who have bleeding disorders. The morphology of anaerobes seen on Gram stain often sets them apart from aerobic organisms. For example, fusobacteria appear as slender Gram-negative rods with sharply pointed ends. Metachromatic granules occasionally occur along the length of the rod in certain species. Bacteroides are seen as irregularly staining, pleomorphic Gram-negative rods. Anaerobic Gram-positive cocci may be challenging to distinguish from their aerobic counterparts, staphylococci, and streptococci. Still, the occurrence of Gram-positive cocci in combination with anaerobic Gram-negative rods may indicate the presence of an anaerobic infection. Mycobacterial and fungal infections may mimic bacterial processes, and for this reason, acid-fast, and potassium hydroxide preparations also should be carefully examined. Quite often, the presence of anaerobes is first suspected after purulent material has failed to grow when incubated aerobically. The physician should then request anaerobic culture of specimens obtained from transtracheal aspiration or thoracentesis. Such material should also be cultured for mycobacteria and fungi. Anaerobes' successful recovery requires careful attention to collecting, transportation, and processing the culture specimen since these microorganisms are quite sensitive to oxygen. Blood, transtracheal or direct lung aspirate, and empyema fluid are suitable for recovering anaerobic isolates. Using a syringe for collecting purulent material is helpful in that all air can be immediately expelled after collection.

The etiology of anaerobic aspiration pneumonia is often presumptive, but sputum cultures should be tried in hospitalized patients to exclude aerobic respiratory pathogens. Febrile patients should have blood cultures. If present, pleural fluid, should be collected for stains and cultures. Individuals who present with typical features of lung abscess, which include a predisposition for aspiration, periodontal disease, sputum with a foul odor, one or more thick-walled cavities independent bronchopulmonary segments (e.g., a posterior segment of the upper lobe or superior segment of the lower lobe when aspirating in the supine position) with air-fluid levels should need further initial diagnostic work-up and be treated presumptively for polymicrobial anaerobic infection. In these cases, expectorated sputum is of no value for detecting anaerobes but may be helpful to exclude the presence of other organisms effective in causing pulmonary infection. Upper lobe cavities without air-fluid levels indicate tuberculosis and require exclusion of *Mycobacterium tuberculosis* with three-morning sputum collections for mycobacterial stains and cultures. Computed tomography of the chest may be essential to define pathologic anatomy. Also, computed tomography, bronchoscopy, bronchoalveolar lavage, and lung biopsy may be necessary for some patients, especially those who do not respond to empirical therapy for lung abscess to exclude non-infectious conditions, such as:

- Cystic bronchiectasis, cavitating neoplasms, and Wegener's granulomatosis may also produce cavitation and confuse lung abscess.

## Clinical Course

Uncomplicated aspiration pneumonia generally responds promptly to appropriate antibiotics. Fever resolves within a few days, and the chest radiograph normalizes within three weeks. Fever resolves more slowly in anaerobic pleuropulmonary infection. Closure of abscess cavities and resorption of empyema collections may require months. Fatality rates are low inadequately treated patients, except those with necrotizing pneumonia, in which mortality approaches 20%. Chronic lung abscess has been complicated by brain abscess, another metastatic abscess, secondary amyloidosis, life-threatening hemoptysis, bronchopleural fistula, or empyema necessitans (rupture through the chest wall), but these complications are currently rare.

## Treatment

The emergence of  $\beta$ -lactamase-mediated resistance mandates that penicillin G and ampicillin are no longer the drugs of choice for treating patients with serious anaerobic pleuropulmonary infection. There is resistance not only among *Bacteroides* species but also among *Prevotella* and some *F. nucleatum* strains. Empirical treatment for severe anaerobic pleuropulmonary infection requires a  $\beta$ -lactam/ $\beta$ -lactamase inhibitor (e.g., ampicillin-sulbactam, ticarcillin-clavulanate, or piperacillin-tazobactam) or clindamycin. Because of the frequent simultaneous presence of aerobes, metronidazole monotherapy is not adequate for suspected anaerobic pneumonia. Occasional pulmonary isolates are resistant to one or more of these agents. For example, *Eikenella corrodens* is resistant to clindamycin. Carbapenem monotherapy is also effective but generally provides unnecessarily broad coverage. Ten days of total treatment is usually adequate for uncomplicated pneumonitis. Necrotizing pneumonia, abscess, and empyema require prolonged parenteral therapy to achieve clinical improvement, and extended courses of oral therapy, often requiring several months, may be required for cure. Drainage of empyema fluid is required. Surgical resection of anaerobic lung abscess is rarely indicated. Bronchoscopy helps exclude an underlying malignancy in patients without other risk factors (i.e., edentulous patients).

## Treatment with older antimicrobial agents

Penicillin, either 500-750 mg every 6 hours orally or 10- 20 million units intravenously per day, or tetracycline had been the standard antimicrobial agents used in empirical regimens to treat putative anaerobic lung abscess. However, many anaerobic Gram-negative respiratory organisms are now found to be penicillin-resistant because of  $\beta$ -lactamase production and tetracycline-resistant. Initially, clindamycin can be used intravenously in doses of 600 mg every 8 hours in hospitalized patients who cannot tolerate oral therapy or orally in doses of 300 mg every 6 hours. Other older agents active against both the oral anaerobes and microaerophilic streptococci include the carbapenem (imipenem and meropenem), cefoxitin,  $\beta$ -lactamase/ $\beta$ -lactam antibiotic combinations (e.g., amoxicillin/clavulanate, ampicillin/sulbactam,

ticarcillin/clavulanate, or piperacillin/tazobactam), or metronidazole combination [17-20]. Metronidazole alone is inadequate therapy for anaerobic pleuropulmonary infections, apparently because it is inactive against microaerophilic streptococci, although it is reliably active against Gram-negative anaerobes. Chloramphenicol is reliably active in-vitro against anaerobes. Although it has effectively treated anaerobic infections, this drug is rarely used because it can cause fatal aplastic anemia and alternative therapy is available.

## Treatment with Novel Antimicrobial Agents

Besides the older drugs, several new antimicrobial agents have been approved to treat respiratory tract infections because of illustrated efficacy in clinical studies of community-acquired pneumonia. Anyhow, none of these drugs has been studied in a group of patients with bacteriologically confirmed anaerobic pleuropulmonary infections or with putative anaerobic infections, such as putrid lung abscess. These drugs have good activity against aerobic respiratory pathogens, such as:

- *H. influenzae*, *Moraxella catarrhalis*, and *S. pneumoniae* have emerged resistant to the older antimicrobial agents. They are also active against the 'atypical' pathogens, such as *Chlamydia pneumoniae*, *Mycoplasma pneumoniae*, and *Legionella pneumophila*.

The *in-vitro* activity demonstrated against various anaerobic bacteria indicates that these newer drugs may have clinical efficacy in anaerobic pleuropulmonary infections.

## New Fluoroquinolones

The older fluoroquinolones, such as ofloxacin, norfloxacin, ciprofloxacin, enoxacin, and lomefloxacin, are inactive against anaerobes. Trovafloxacin, gatifloxacin, moxifloxacin, gemifloxacin, and to a limited extent, sparfloxacin levofloxacin are active against anaerobes. The use of trovafloxacin is severely limited by the rare occurrence of hepatotoxicity that has been fatal in some cases. The occurrence of phototoxicity limits the use of sparfloxacin. Side effects with gatifloxacin, levofloxacin, and moxifloxacin have been minimal. However, prolongation of the Q-Tc interval in some patients with sparfloxacin, gatifloxacin, and moxifloxacin has resulted in the recommendation that their use is avoided in patients with known prolongation of the Q-Tc interval, patients with uncorrected hypokalemia, and patients receiving class 1A or class III antiarrhythmic agents. As their broad spectrum of activity for respiratory pathogens and the infrequency of significant side effects, these newer fluoroquinolones have been commonly used for empirical therapy of pneumonia. Certainly, the latest Infectious Disease Society of America (IDSA) guidelines for treating community-acquired pneumonia recommended their use, either

- Alone for treatment of outpatients or
- Combined with a  $\beta$ -lactam, such as ceftriaxone, to treat patients requiring intensive care unit admission.

Combination therapy was recommended because its efficacy, when used alone in severe pneumonia, has not been documented. For doubted aspiration, the IDSA recommended a newer fluoroquinolone with or without a  $\beta$ -lactam or  $\beta$ -lactamase inhibitor combination, such as ampicillin/sulbactam or piperacillin/tazobactam, metronidazole, or clindamycin. A Centers for Disease Control and Prevention (CDC) panel recently convened to consider treatment of community-acquired pneumonia in the face of emerging antimicrobial resistance was hesitant to recommend the newer fluoroquinolones for fear that their widespread use may lead to the development of fluoroquinolone resistance among the respiratory pathogens (and other pathogens colonizing the treated patients). The CDC panel did not especially comment on the treatment of anaerobic pulmonary infection.

## Ketolides

These are a new group of antimicrobial agents that are structurally related to the macrolides. Ketolides mechanism of action is similar to that of the macrolides, which blocks protein synthesis by binding to the ribosomal RNA complex. Bacteria that either display Macrolide-lincosamide-streptogramin B (MLSB) type of resistance (i.e., cross-resistant to clindamycin, macrolides, and streptogramin B) as a result of decreased affinity to an altered ribosomal target or exhibit efflux type of resistance (i.e., susceptible to clindamycin but resistant to macrolides) are still susceptible to the ketolides [21]. Telithromycin, a ketolide, is active against streptococci and staphylococci resistance to the macrolides. Also, Telithromycin is active against many anaerobes, with minimal inhibitory concentration (MIC) of 40.5 mg/ml [22]. Telithromycin is well absorbed when given in doses of 800 mg every 24 hours per oral achieves peak and trough serum levels of about 2 mg/ml and 0.05 mg/ml, respectively, and has a serum half-life of 10 hours [23]. It is concentrated  $\geq 100$ -fold within phagocytes and about 5-fold in the epithelial lining fluid of the alveoli.

## Oxazolidinones

Linezolid, a new class of synthetic antimicrobial agents, the oxazolidinones, has been approved by the FDA to treat respiratory tract infections. As its unique mechanism of action, cross-resistance with other antimicrobial agents do not occur; linezolid is active against *Fusobacterium spp.*, *Prevotella spp.*, *Porphyromonas spp.*, *Bacteroides spp.*, and *Peptostreptococci* at MIC  $\leq 2$  mg/ml. Linezolid is given in doses of 600 mg intravenously or orally every 12 hours. Linezolid peak and trough serum levels are 12 and 4 mg/ml, whereas its serum half-life is about 4 hours. Doses are the same for renal failure patients. Side effects have been minimal but reversible thrombocytopenia has been reported in about 3% of treated patients. Individuals on effective therapy will defervesce, but in patients with putrid lung abscess, the sputum will become odorless within a week. The duration of therapy is controversial, and chest radiographic findings may take several weeks to resolve. The recommended duration of therapy for aspiration pneumonia is 14 days. It is

usually 4-6 weeks for anaerobic lung abscess to prevent relapse or until the abscess completely resolves or a small, stable residual scar. After several weeks, many patients will stop taking medication independently and return later for other reasons with a clear chest radiogram. Failure to respond to therapy (persistent fever, worsening of the pulmonary radiographic findings, or development of empyema) should prompt more intensive investigation to exclude the presence of resistant pathogens or a non-infectious etiology. Surgery is rarely indicated for putrid lung abscesses, except for the rare complication of massive hemoptysis. Traditionally, chest physiotherapy, postural and bronchoscopic drainage have been recommended to build up antimicrobial therapy. However, caution should be used to avoid sudden massive emptying of pus-filled cavities into the airways and previously uninvolved bronchopulmonary segments. Anaerobic empyema requires complete drainage, usually by inserting a chest tube, although thoracotomy and rib resection may be necessary to break loculations to accomplish this.

## Surgery

Currently, indications for surgery other than for drainage of empyema are:

- Life-threatening hemorrhage
- Bronchial obstruction with poor drainage
- Associated symptomatic bronchiectasis
- Lung cancer

## Conclusion

Obligate anaerobes are the chief constituents of normal oropharyngeal flora and produce pleuropulmonary infection in individuals who are prone to aspirate. The diagnosis and treatment of anaerobic pulmonary infection are frequently empirical and guided by published studies of in-vitro activity against collected clinical isolates. Various new drugs with in-vitro activity against obligate anaerobes have recently become available for empirical treatment of pneumonia. Anaerobic pleuropulmonary infections most frequently occur after the aspiration of oral secretions. These infections are polymicrobial and are manifested as pneumonia, lung abscess, or empyema. The three predilection sites are the posterior segment of the right upper lobe and the superior segment of the right and left lower lobes. Diagnosis depends on the clinical picture, especially the presence of foul-smelling sputum or empyema fluid and radiologic and bacteriologic clues. Gram stain of material obtained by transtracheal aspiration or thoracentesis usually provides a definitive diagnosis. Parenteral administration of penicillin G is preferred for the initial treatment of all forms of anaerobic pleuropulmonary infection; indications for surgery are few.

**Conflict of Interest:** None

**Ethical Consideration:** Not applicable

## References

- Murray & Nadel's Textbook of Respiratory Medicine SIXTH EDITION, volume 1
- Green SL. Anaerobic pleuropulmonary infections. *Postgraduate medicine*. 1979 Jan 1; 65(1):62-74.
- Levison ME. Anaerobic pleuropulmonary infection. *Infectious Diseases in Clinical Practice*. 2002 Mar 1; 11(3):131-6.
- Hill D.A., Ivanovich J., Priest J.R., Gurnett C.A., Dehner L.P., Desruisseau D., Jarzembowski J.A., Wikenheiser-Brokamp K.A., Suarez B.K., Whelan A.J., et al. Germline DICER1 Mutations in Familial Pleuropulmonary Blastoma. *Science*. 2009;325:965. doi: 10.1126/science.1174334.
- Foulkes W.D., Priest J.R., Duchaine T.F. DICER1: Mutations, microRNAs and mechanisms. *Nat. Rev. Cancer*. 2014;14:662-672. doi: 10.1038/nrc3802.
- Schultz K.A., Yang J., Doros L., Williams G.M., Harris A., Stewart D.R., Messinger Y., Field A., Dehner L.P., Hill D.A. DICER1-pleuropulmonary blastoma familial tumor predisposition syndrome: A unique constellation of neoplastic conditions. *Pathol. Case Rev*. 2014;19:90-100. doi: 10.1097/PCR.000000000000027.
- Calin G.A., Croce C.M. MicroRNA signatures in human cancers. *Nat. Rev. Cancer*. 2006;6:857-866. doi: 10.1038/nrc1997.
- Yang W.J., Yang D.D., Na S., Sandusky G.E., Zhang Q., Zhao G. Dicer is required for embryonic angiogenesis during mouse development. *J. Biol. Chem*. 2005;280:9330-9335. doi: 10.1074/jbc.M413394200.
- Faure A., Atkinson J., Bouty A., O'Brien M., Levard G., Hutson J., Heloury Y. DICER1 pleuropulmonary blastoma familial tumour predisposition syndrome: What the paediatric urologist needs to know. *J. Pediatr. Urol*. 2016;12:5-10. doi: 10.1016/j.jpuro.2015.08.012.
- Priest J.R., Watterson J., Strong L., Huff V., Woods W.G., Byrd R.L., Friend S.H., Newsham I., Amylon M.D., Pappo A., et al. Pleuropulmonary blastoma: A marker for familial disease. *J. Pediatr*. 1996;128:220-224. doi: 10.1016/S0022-3476(96)70393-1.
- Fletcher J.A., Perez-Atayde A.R., Nosé V., Vargas S.O. Gains of Chromosome 8 Are Confined to Mesenchymal Components in Pleuropulmonary Blastoma. *Pediatr. Dev. Pathol*. 2001;4:434-445.
- Yang P., Hasegawa T., Hirose T., Fukumoto T., Uyama T., Monden Y., Sano T. Pleuropulmonary Blastoma: Fluorescence In Situ Hybridization Analysis Indicating Trisomy 2. *Am. J. Surg. Pathol*. 1997;21:854-859. doi: 10.1097/0000478-199707000-00015.
- Pugh T.J., Yu W., Yang J., Field A.L., Ambrogio L., Carter S.L., Cibulskis K., Giannikopoulos P., Kiezun A., Kim J., et al. Exome sequencing of pleuropulmonary blastoma reveals frequent biallelic loss of TP53 and two hits in DICER1 resulting in retention of 5p-derived miRNA hairpin loop sequences. *Oncogene*. 2014;33:5295-5302. doi: 10.1038/onc.2014.150.
- Schultz K.A.P., Williams G.M., Kamihara J., Stewart D.R., Harris A.K., Bauer A.J., Turner J., Shah R., Schneider K., Schneider K.W., et al. DICER1 and Associated Conditions: Identification of At-risk Individuals and Recommended Surveillance Strategies. *Clin. Cancer Res*. 2018;24:2251-2261. doi: 10.1158/1078-0432.CCR-17-3089.
- Sabapathy D.G., Guillerman R.P., Orth R.C., Zhang W., Messinger Y., Foulkes W., Priest J.R., Annapragada A.V. Radiographic Screening of Infants and Young Children With Genetic Predisposition for Rare Malignancies: DICER1 Mutations and Pleuropulmonary Blastoma. *Am. J. Roentgenol*. 2015;204:475-482. doi: 10.2214/AJR.14.12802.
- David M., Lamas-Pinheiro R., Henriques-Coelho T. Prenatal and Postnatal Management of Congenital Pulmonary Airway Malformation. *Neonatology*. 2016;110:101-115. doi: 10.1159/000440894.
- Nasr A., Himidan S., Pastor A.C., Taylor G., Kim P.C. Is congenital cystic adenomatoid malformation a premalignant lesion for pleuropulmonary blastoma? *J. Pediatr. Surg*. 2010;45:1086-1089. doi: 10.1016/j.jpedsurg.2010.02.067.
- Dosios T., Stinios J., Nicolaidis P., Spyrakos S., Androulakakis E., Constantopoulos A. Pleuropulmonary blastoma in childhood. A malignant degeneration of pulmonary cysts. *Pediatr. Surg. Int*. 2004;20:863-865. doi: 10.1007/s00383-003-0997-2.
- Priest J.R., Williams G.M., Hill D.A., Dehner L.P., Jaffe A. Pulmonary cysts in early childhood and the risk of malignancy. *Pediatr. Pulmonol*. 2009;44:14-30. doi: 10.1002/ppul.20917.
- Lezmi G., Verkarre V., Khen-Dunlop N., Vibhushan S., Hadchouel A., Rambaud C., Copin M.-C., Rittié J.-L., Benachi A., Fournet J.-C., et al. FGF10 Signaling differences between type I pleuropulmonary blastoma and congenital cystic adenomatoid malformation. *Orphanet J. Rare Dis*. 2013;8:130. doi: 10.1186/1750-1172-8-130.
- Leblanc C., Baron M., Desselas E., Phan M.H., Rybak A., Thouvenin G., Lauby C., Irtan S. Congenital pulmonary airway malformations: State-of-the-art review for pediatrician's use. *Eur. J. Nucl. Med. Mol. Imaging*. 2017;176:1559-1571. doi: 10.1007/s00431-017-3032-7.
- Robinson A., Romao R., Mills J., Davies D.A. Decision-Making Criteria for Observational Management of Congenital Pulmonary Airway Malformations (CPAMs) *J. Pediatr. Surg*. 2018;53:1006-1009. doi: 10.1016/j.jpedsurg.2018.02.035.
- Downard C.D., Calkins C.M., Williams R.F., Renaud E.J., Jancelewicz T., Grabowski J., Dasgupta R., McKee M., Baird R., Austin M.T., et al. Treatment of congenital pulmonary airway malformations: A systematic review from the APSA outcomes and evidence based practice committee. *Pediatr. Surg. Int*. 2017;33:939-953. doi: 10.1007/s00383-017-4098-z.



Submit your manuscript to the  
World Journal of Case Reports and Clinical Images  
and benefit from:

- Convenient online submission
- Rigorous peer review
- Immediate publication on acceptance
- Open access: articles freely available online
- High visibility within the field
- Retaining the copyright to your article

*Submit your manuscript at*  
<https://worldjournalofcasereports.org/>

&  
wjcasereports@gmail.com;  
submission@worldjournalofcasereports.org

